

DIAGNOSTIC ASPECTS OF DEGENERATE - DYSTROPHIC CHANGES OF THE CERVICAL DEPARTMENT OF THE BACKBONE AT THE PATIENTS WHO HAVE ACTED ON SANATORIUM REHABILITATION
V.A. Chernorotov

SUMMARY

The roentgenologic displays of degenerative-dystrophic changes of cervical spine in 200 patients acting on a sanatorium-resort rehabilitation were analyzed. Researches showed that the roentgenologic displays of these changes can be localised in intervertebral disks, in the bodies of vertebrae, in zygapophyseal and another joints, in ligaments, in soft tissues, surrounding a spine, vertebral channel.

200

60-90% 50

40-50% [7, 9, 10].

[1].

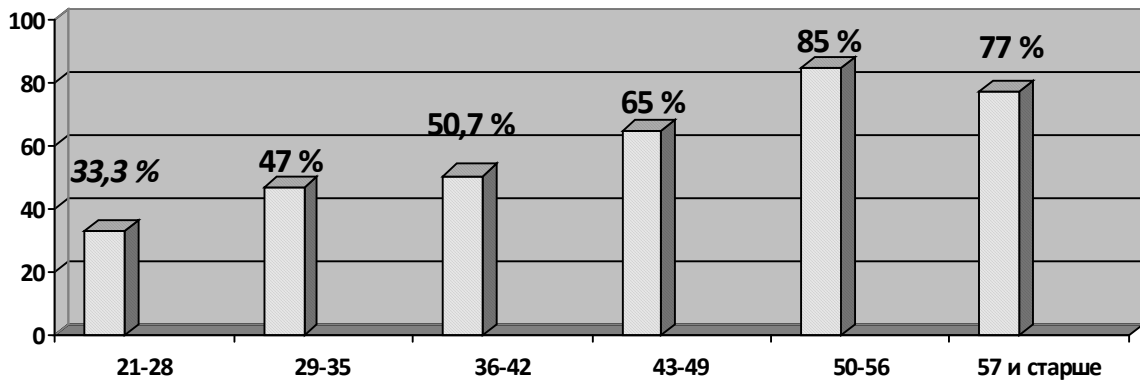
(10°)

4 5

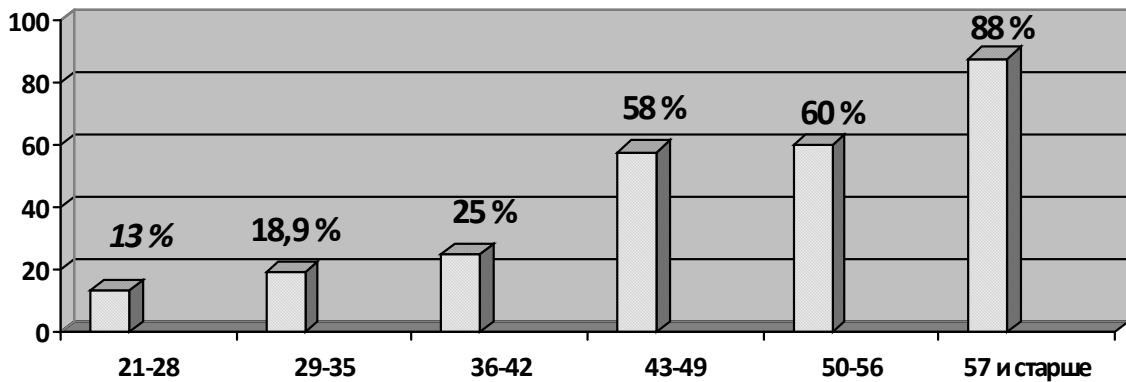
[2, 5, 6].

1.	1.
2.	()
3.	2.
4.	
5.	

« » 156 , . .
 - 78% . 16 -
 - , ,
 - .
 -
 -
 - 21
 -
 , . . (78%). 26%.
 -
 21 - 28, 29 - 35 , 33,
 « » « » 3% 47% (. 1).

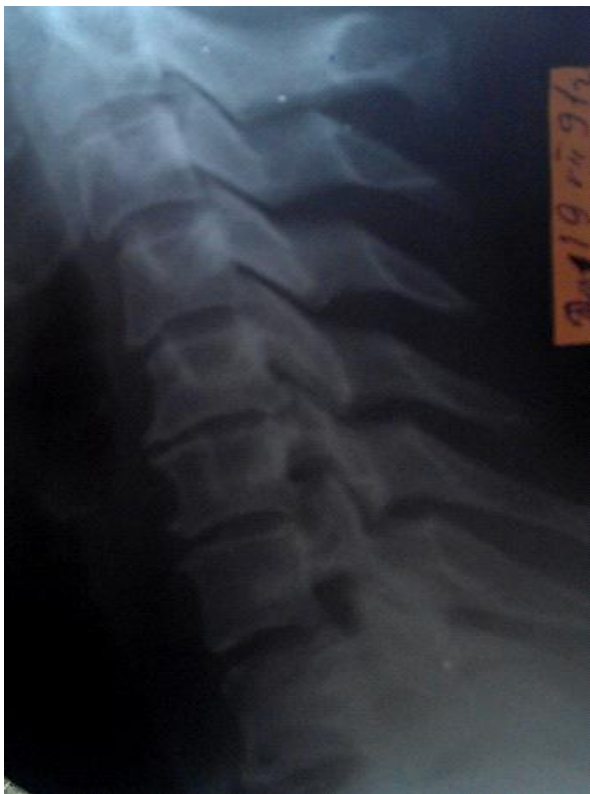

. 1.

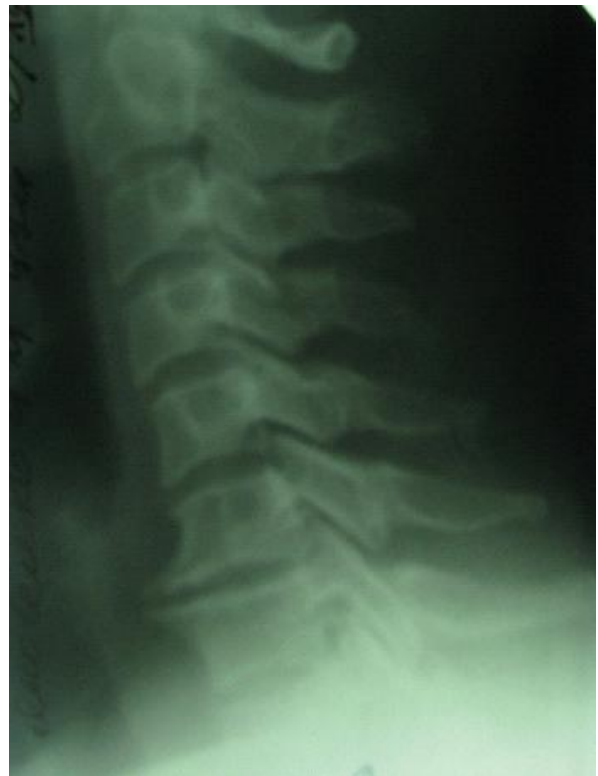

. 2.

36-42 43 - 49 . - I -
 50,7 % 65 % . -
 (.2).
 50-56 57 106 , - 6.
 88 % (.2), « » . -
 , , -
 , , -
 80-120 . , -
 , -
 12 , 7- , 5- (.3).
 106 , -
 , 6 -
 . 11 -
 5 2-3 . 4- II -
 (1973). 78 (38%) .



.3. .42 .



.4. ., 49 .

5- 7,
 , 5- 6.

, 6- 7,
 6 7,

