

LENALIDOMIDE-BASED COMBINED THERAPY INDUCED ALTERATIONS IN SERUM PROTEINS OF MULTIPLE MYELOMA PATIENT: A FOLLOW-UP CASE REPORT AND OVERVIEW OF THE LITERATURE

C.S. Senthilkumar*, N. Ganesh

Clinical Cytogenetic Laboratory, Department of Research,
Jawaharlal Nehru Cancer Hospital & Research Centre (JNCHRC), Bhopal — 462 001 Madhya Pradesh, India

Aim: Multiple myeloma (MM) is a malignant neoplasm of plasma cells (PC) derived from the bone marrow (BM) origin. The present case report was aimed to monitor the efficiency of lenalidomide-based combined therapy (LBCT) induced alterations in serum proteins of 42-year-old female MM patient. Besides, in the context of case report we also present an overview of the literature describing LBCT. **Study design:** Serum protein electrophoresis (SPEP) was performed in three visits (V_1 - V_3) to monitor the disease status of the patient and her treatment response to LBCT. Level of monoclonal protein (M-protein) was measured through cellulose acetate zone electrophoresis and quantified by densitometer in follow-up investigations after therapy intervals. **Results:** A significant reduction of M-protein in γ -globulin region was observed ($P < 0.007$) after receiving LBCT. However, the condition depicted hyper γ -globulinemia. β -globulin ($P < 0.002$) and α_2 -globulin ($P < 0.047$) was suppressed from the initial visit and subsequent follow-up also indicated the status of hypoglobulinaemia. Although, serum albumin level was found to be increased after therapy ($P < 0.016$), hypoalbuminaemia was also noticed before and after LBCT. **Conclusion:** On the basis of this case report and pertinent literature, we conclude that LBCT is more efficient in the treatment of MM and has significant role in serum protein alterations especially in the reduction of M-protein in the MM patients.

Key Words: disease response monitoring; lenalidomide-based combined therapy; multiple myeloma; three visits follow-up; serum protein alterations.

Multiple myeloma (MM) is a malignancy of plasma cells (PC) of bone marrow (BM) [1]. MM begins with the elevated number of PC secretes whole monoclonal immunoglobulin's (Ig) or high level of homogenous M-proteins [2]. M-protein secreting PC grows primarily in the BM cavities and proliferates from one cavity to another. MM may progress as asymptomatic or symptomatic forms and their complications include unexplained bone pain, typical elevated serum protein or urinary protein, hypercalcemia, renal impairment, amyloidosis, immunodeficiency and anemia [3, 4].

Hematological, biochemical, radiological and immunological investigations have gained more attention in establishing the diagnosis and management of MM. SPEP is the one considered as a hallmark immunological investigation in the diagnosis of MM over years. SPEP identifies clinically significant M-protein spike or paraprotein. M-protein is a tumor marker for monoclonal gammopathies used to monitor the disease status. Monoclonal gammopathy is defined with a homogeneous spike-like peak in a focal region of the γ — globulin [5]. Based on the diagnosis including SPEP, MM patient must be subjected to chemotherapy

in a plateau state or for one year [6]. Many novel drugs like bortezomib, thalidomide and lenalidomide has made better understanding of MM treatment substantially over the last decade [7].

Lenalidomide, an amino-substituted thalidomide derivative is the current choice of drug to treat MM, due to its high beneficial biological and pharmacological properties in management of the disease. It is a well-known oral immunomodulatory drug (IMiD) that lacks the toxicological profile of thalidomide includes significant peripheral neuropathy, somnolence, and constipation [8, 9]. It has a remarkable *in vitro* and *in vivo* activity. Lenalidomide directly induces tumor cell apoptosis [10]. Lenalidomide has the potential to modify ligand induced cellular responses like tumor necrosis factor- α (TNF- α) and interleukin- 1β (IL- 1β). It also stimulates the anti-inflammatory cytokine interleukin-10 (IL-10) [11, 12]. Lenalidomide has a limited toxicity in MM and myelodysplastic patients [13].

International uniform response criteria for MM also recommended that patients undergoing therapy and their measurable disease must be tracked and assessed with SPEP [14]. Keeping in view of the recommendations, the case presented here was monitored for the therapeutic alterations induced by lenalidomide-based combined drugs (LBCT) through SPEP. Besides, in the context of case report we also present an overview of the literature describing similar therapy.

CASE REPORT

A 42-year-old Indian female who initially presented with lower back ache. She is a known hypertensive with

Received: September 23, 2012.

*Correspondence: E-mail: sengenetics@gmail.com

Abbreviations used: BM — bone marrow; CR — complete remission; HM — hematological malignancies; Ig — immunoglobulin; IL — interleukin; IMiD — immunomodulatory drug; LBCT — lenalidomide-based combined therapy; MM — multiple myeloma; M-Protein — monoclonal protein; OD — once a day; PC — plasma cells; SPEP — serum protein electrophoresis; TLC — Total Leucocyte Count; TNF — tumor necrosis factor; V — visit.

tobacco chewing habit. Her past medical history was remarkable with hysterectomy about seven years ago. She was examined by primary care physician reported pedal oedema and tenderness in lumbar spine. She was sent for MRI lumbosacral spine. MRI report revealed generalized osteoporotic changes in spine, indicated the possibility of multiple focal BM neoplastic lesions. Finally, she was subjected to whole body scan with Tc-99m revealed multiple bony metastases. She also had complete blood profile and biochemistry test done and the most notable finding showed Total Leucocyte Count (TLC) 13.700 with an Hgb of 9.8 g/dL and blood urea 79%. Rest all other investigations were normal. Additional studies recommended by the oncologist included SPEP.

Clinical Sample and SPEP. The study was conducted in accordance to the ethical norms of Institutional human ethical committee. Peripheral blood sample were collected in no additive anticoagulant-free vacutainer tubes (VAKU-8, HMD Healthcare, UK) from the patient through department of pathology, Jawaharlal Nehru Cancer Hospital & Research Centre, Bhopal. Zone electrophoresis was performed immediately within two hours after serum separation. Sera were electrophoresed on cellulose acetate paper (Sartorius, Germany) Electrophoresis unit (Bangalore Genei, Bangalore) at 60 V with Tris — Borate — EDTA (pH 8.3) buffer conditions previously described by us [15, 16]. The bands were separated till the dye front reaches the end of cellulose acetate paper and then stained with Ponceau S stain (S.d fine chemicals, Mumbai) and destained with 7% acetic acid for 30 min. Serum protein bands for each fraction were quantified for their absolute values in densitometer (Systronics, India).

Diagnosis and chemotherapy regimen. Initial SPEP analysis of the patient on visit 1 (V_1) revealed a discrete high intense band confirmed the presence of M-protein or strikingly elevated spike in the γ -globulin region. Accordingly to the diagnosis, she was subjected to radiotherapy and chemotherapy with the combined regimen of lenalidomide (25 mg) once a day (OD), Dexamethasone (20 mg/week) and Ibandronic acid (Bisphosphonate) (9 mg/week). Enoxaparin (0.6 ml/OD), Morphine (2 mg/OD), and Metoclopramide (5 mg/OD) were administered as supportive drugs in the regimen. She completed the first cycle LBCT in two weeks. Due to the complaint of continuous vomiting, weakness and pain she was advised to stop lenalidomide. After nine days, she started once again LBCT as second cycle included antibiotics Amikacin (750 mg/OD) and Nitrofurantoin (100 mg/7 days) due to bacterial infections. To monitor the disease and its response to LBCT in the patient, we collected serum samples of visit 2 (V_2) after two weeks of initial therapy (at the end of first cycle) and visit 3 (V_3) after two weeks completion of the second cycle of lenalidomide. In all the visits, SPEP was performed and analyzed as mentioned above.

Statistical analysis. Statistical analysis was done using Graph Pad InStat (GPIS) Ver. 3.05. One Sample

T test were used to analyze the cumulative results in 95% confidence interval, at $p < 0.05$ significance level.

RESULTS

Disease status and response to LBCT was monitored through SPEP in a female MM patient. Comparative analysis was made among the individual protein fractions (albumin, α_1 -globulin, α_2 -globulin, β -globulin and γ -globulin) among initial and follow — up visits (V_1 – V_3).

More significantly, a remarkable reduction of M-protein spike or sharp intense band in the γ -globulin region was observed in V_2 and V_3 when compared to V_1 (59.85 ± 4.97) ($p < 0.007$). Although, the level of M-protein was declined, percentage of γ -globulin was higher and above the normal range even after therapy.

Since from V_1 – V_3 , β -globulin (2.906 ± 0.13) ($p < 0.002$) and α_2 -globulin (5.716 ± 1.28) ($p < 0.0476$) was markedly suppressed and noticed as sharp faint band considerably declined from the normal range. In all three visits, α_1 -globulin was seen as a faint band and appeared within the reference range (8.063 ± 2.12) ($p < 0.063$).

Albumin appeared as a light diffused band and slightly increased after the therapy of V_2 and V_3 as compared to V_1 (21.77 ± 2.75) ($p < 0.016$). However, the low serum albumin level failed to attain the normal range in V_2 and V_3 (Table, Figure).

Table. Serum protein profile of MM patient in three consequent visits

Serum proteins (reference range, %)	V_1 (BT)	V_2 (AT)	V_3 (AT)	Mean \pm SE	One sample t-test
Albumin (42–60)	16.33	23.79	25.21	21.77 ± 2.75	$t = 7.907$ $p < 0.015^*$
α_1 -globulin (2–11)	3.92	10.91	9.36	8.06 ± 2.12	$t = 3.804$ $p < 0.063$
α_2 -globulin (9–21)	7.79	3.38	5.98	5.72 ± 1.28	$t = 4.467$ $p < 0.047^*$
β -globulin (4.5–15)	3.16	2.72	2.84	2.91 ± 0.13	$t = 22.135$ $p < 0.002^*$
γ -globulin (9–25)	68.78	59.17	51.61	59.85 ± 4.97	$t = 12.047$ $p < 0.007^*$

Notes: BT – before therapy; AT – after therapy; * – significance.

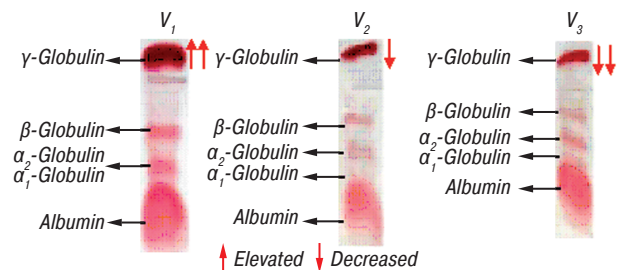


Figure. Protein profile in serum of MM patient showing the discrete intense band of “Myeloma Protein” decreased after receiving LBCT — Elevated — Decreased

DISCUSSION

MM is an uncommon cancer occurs approximately 10–20% of all hematological malignancies (HM) [17]. Several anticancer chemotherapeutic drugs are known to alter the immune cell functions and also used as an immunosuppressant [18]. Lenalidomide is an IMiD, frequently used to treat MM, HM and solid tumors. Hence, the case presented here was monitored for the therapeutic effects of LBCT on serum proteins.

Many studies suggested that the LBCTs are highly effective to treat MM. Even though lenalidomide has

an antitumor activity, some MM patients do not respond to monotherapy [19]. Lenalidomide monotherapy in MM may possibly delay in complete remission (CR) of the disease and drug must be administered for a long period to achieve stable remission. Such long administration may cause side effects. A phase II study revealed 25% of relapsed or refractory MM patients treated with lenalidomide showed a complete and partial response. However, these patients failed to respond lenalidomide monotherapy, 29% of the patients responded after the addition of oral dexamethasone [20]. Another study observed lenalidomide plus dexamethasone combined therapy as a highly effective regimen to treat refractory MM as compared to the old therapy consisting of high-dose dexamethasone alone [21].

An open-label phase II trial, studied 72 symptomatic MM naive patients received oral lenalidomide (25 mg/OD) for 21 days, clarithromycin (500 mg) twice daily, and dexamethasone (40 mg) once weekly every 28 days. This study significantly observed a reduction of serum M-protein $\geq 50\%$ and urine M-protein $\geq 90\%$ was noticed in 90% of patients ($n = 65$). Maximum complete response rate was 39%, with 74% of patients showed a decrease in M-protein levels around 90% [22]. The response rate of other LBCT regimen (Dexamethasone, bortezomib and cyclophosphamide) is also more encouraging in the treatment of relapsed or refractory MM achieved CR [9].

Our patient has shown a remarkable response after receiving the LBCT demonstrated the stable reduction of M-protein. Considerable decrease of M-protein level indicated patient's response to combined therapy. However, hyper γ -globulinemia was retained in the patient even after the therapy. Furthermore, the combined regimen is highly effective than any other monotherapy and administered regularly to achieve CR in the patient. Regular administration of lenalidomide may have reduced side effects in the MM patient [13].

Besides, other globulin proteins (β and α_2) persisted in a suppressive state indicated the condition of hypoglobulinaemia before and after therapy. Remarkably, the status of α_1 -globulin was normal in the patient even after receiving two cycles of lenalidomide. Low serum albumin level or hypoalbuminaemia commonly occurs in myeloblastic or lymphoblastic leukemic events [23]. In agreement to this hypothesis, hypoalbuminaemia was also existed in the patient before and after therapy, a slight increase in albumin status indicated the positive response only after the initial therapy. However, the case report presented here illustrated the condition of monoclonal gammopathy in all three visits.

The present case findings are concordance to the report of Weber et al. [21] and Niesvizky et al. [22], suggested that CR in MM patients can be achieved on LBCT. However, the present study failed to monitor the MM patient till CR, due to her irregular follow-up and discharge. But, this three visit follow-up noticed a better response of the MM patient on LBCT. It is also noteworthy to mention that LBCT has a significant role in the reduction of M-protein. This reduction may be due to the

immunomodulating activity of lenalidomide. On the basis of case report we suggest that LBCT regimen is effective against MM and must be implemented for treating other cancers similar to MM.

Although this follow-up report has few limitations, the case reported here exhibits the advantage and efficiency of LBCT, which could be useful to the laboratory clinicians and oncologists in treating MM. Effective treatment of cancer needs a proper chemotherapeutic regimen and monitoring attains CR in the patients. Hence, this kind of case report is essential in future to reveal the therapeutic effect of drugs in cancer treatment.

In summary, this case report highlights the significance of monitoring serum protein alterations especially M-protein through SPEP. We conclude that LBCT has a potent role in treating MM.

ACKNOWLEDGEMENT

The authors thank the management of JNCHRC especially Chairman Mr. Madan Mohan Joshi, Institute Director Dr. K.V. Pandya, Medical Director and Radiation oncologist R. K. Pandey, Addt. Director Mr. Rakesh Joshi, Research coordinator Mrs. Divya Parashar for research support.

REFERENCES

1. Kyle RA, Rajkumar SV. Multiple myeloma. *Blood* 2008; 111: 2962–72.
2. Lynch HT, Sanger WG, Pirruccello S, *et al.* Familial multiple myeloma: a family study and review of the literature. *J Natl Cancer Inst* 2001; 93: 1479–83.
3. IMWG (International Myeloma Working Group). Criteria for the classification of monoclonal gammopathies, multiple myeloma and related disorders: a report of the International Myeloma Working Group. *Br J Haematol* 2003; 121: 749–57.
4. Fentress DS, Orrico LA, Kruspe M, Briscoe K, *et al.* Multiple myeloma. *Hospital Physician* 2006; 42: 15–25.
5. O'Connell TX, Horita TJ, Kasravi B. Understanding and interpreting serum protein electrophoresis. *Am Fam Physician* 2005; 71: 105–12.
6. Kyle RA. Update on the treatment of multiple myeloma. *Oncologist* 2001; 6: 119–24.
7. Richardson PG, Mitsiades C, Schlossman R, Munshi N, *et al.* New drugs for myeloma. *Oncologist* 2007; 12: 664–89.
8. Palumbo A, Miguel Js, Sonneveld P, *et al.* Lenalidomide: A new therapy for multiple myeloma. *Cancer Treat Reviews* 2008; 34: 283–91.
9. Lonial S, Mitsiades CS, Richardson PG. Treatment options for relapsed and refractory multiple myeloma. *Clin Cancer Res* 2011; 17: 1264–77.
10. Vallet S, Palumbo A, Raje N, Boccadoro, *et al.* Thalidomide and lenalidomide: mechanism-based potential drug combinations. *Leuk Lymphoma* 2008; 49: 1238–45.
11. Crane E, List A. Lenalidomide: an immunomodulatory drug. *Future Oncol* 2005; 1: 1–5.
12. List AF, Baker AF, Green S, Bellamy W. Lenalidomide: targeted anemia therapy for myelodysplastic syndromes. *Cancer Control* 2006; 13: 4–11.
13. Volk C, Klein U. Management of multiple myeloma and myelodysplastic syndrome: focus on lenalidomide. *Clinical Medicine: Therapeutics* 2009; 1: 95–102.

14. Durie BGM, Harousseau J-L, Miguel JS, *et al.* International uniform response criteria for multiple myeloma. *Leukemia* 2006; **20**: 1467–73.

15. Senthilkumar CS, Ujjwala K, Sameena A, Ganesh N. Consistency pattern of liver functioning, serum proteins and genomic DNA in hematological malignancies: a comparative clinical study in 4 cases of chronic and acute leukemia's. *Int J Cell Mol Biol* 2010; **1**: 19–25.

16. Senthilkumar CS, Malla TM, Ujjwala K, Sameena A, *et al.* Amido black 10 B is preferable to Ponceau S stain for staining Serum proteins in electrophoretic studies for clinical diagnosis. *J Ult Sci Phy Sci* 2009; **21**: 105–8.

17. Piazza FA, Gurrieri C, Trentin L, Semenzato G. Towards a new age in the treatment of multiple myeloma. *Ann Hematol* 2007; **86**: 159–72.

18. Zitvogel L, Apetoh L, Ghiringhelli F, Kroemer G. Immunological aspects of cancer chemotherapy. *Nat Rev Immunol* 2008; **8**: 59–73.

19. Hideshima T, Richardson PG, Anderson KC. Current therapeutic uses of lenalidomide in Multiple myeloma. *Expert Opin Invest Drugs* 2006; **15**: 171–9.

20. Richardson PG, Blood E, Mitsiades CS, *et al.* A randomized phase II study of lenalidomide therapy for patients with relapsed or relapsed and refractory multiple myeloma. *Blood* 2006; **108**: 3458–64.

21. Weber DM, Chen C, Niesvizky R, *et al.* Lenalidomide plus dexamethasone for relapsed multiple myeloma in North America. *The New Eng J Med* 2007; **357**: 2133–42.

22. Niesvizky R, Jayabalan DS, Christos PJ, *et al.* BiRD (Biaxin [clarithromycin]/Revlimid [lenalidomide]/dexamethasone) combination therapy results in high complete — and overall response rates in treatment-naive symptomatic multiple myeloma. *Blood* 2008; **111**: 1101–9.

23. Fahey JL, Boggs DR. Serum protein changes in malignant diseases. I. The acute leukemia's. *Blood* 1960; **16**: 1479–90.