

UDC 567.895.122:594.3

CHANGES IN THE STRUCTURE AND FUNCTIONS OF MOLLUSC ORGANS UNDER THE EFFECT OF *ORIENTOBILHARZIA TURKESTANICA* LARVAE

U. A. Shakarbaev¹, A. S. Mingbaev², F. D. Akramova¹, E. B. Shakarboev¹, D. A. Azimov¹

¹ Institute of Plant and Animal Gene Pool, Academy of Sciences of Uzbekistan,

² Tashkent Municipal Cancer Center

Institute of Plant and Animal Gene Pool,
Academy of Sciences of the Republic of Uzbekistan,
Durman-yul str., 32, Tashkent, 100125 Uzbekistan
E-mail: ushakarbaev@mail.ru

Changes in the Structure and Functions of Mollusc Organs under the Effect of *Orientobilharzia turkestanica* Larvae. Shakarbaev U. A., Mingbaev A. S., Akramova F. D., Shakarboev E. B., Azimov D. A. — The paper presents results of the studies on alterations in the structure and functions of mollusc organs under the effect of the trematode *Orientobilharzia turkestanica* (Skrjabin, 1913) larvae. Destructive changes were observed along with a vast necrosis of the hepatopancreatic gland. Parasitism of *O. turkestanica* parthenitae and cercariae in *L. auricularia* causes deep histopathological changes in the tissues. Protein, carbohydrate and fat metabolism disorders result in the weakening of molluscs and loss of their lability, which is essential for adaptation to environmental changes. The latter is confirmed by a high mortality of infected individuals.

Key words: trematodes, *Orientobilharzia turkestanica*, molluscs, *Lymnaea auricularia*, parthenitae, cercariae, histological structure.

Изменения структуры и функций органов моллюсков под влиянием личинок *Orientobilharzia turkestanica*. Шакарбаев У. А., Мингбаев А. С., Акрамова Ф. Д., Шакарбоев Э. Б., Азимов Д. А. — Приведены результаты исследований изменения структуры и функций органов моллюсков под влиянием личинок трематоды *Orientobilharzia turkestanica* (Skrjabin, 1913). На фоне обширного некротического распада гепатопанкреатической железы наблюдаются деструктивные изменения. Паразитирование партенит и церкарий *O. turkestanica* в организме *L. auricularia* вызывает глубокие гистопатологические изменения тканей. При этом происходят нарушения белкового, углеводного и жирового метаболизма, что ослабляет организм моллюсков и приводит к потере их лабильности, столь необходимой для приспособления к изменяющимся условиям среды. Последнее подтверждается высокой гибелью инвазированных особей.

Ключевые слова: трематоды, *Orientobilharzia turkestanica*, моллюски, *Lymnaea auricularia*, партениты, церкарии, гистоструктура.

Introduction

Parasitism of parthenogenetic generations of trematodes in the mollusc body leads to the collapse of different organs and often disturbs normal metabolic activity of the host. Damaging effect of parthenitae may be due to mechanical host-mollusc tissues destruction, nutritive absorption and poisoning of mollusc organism by metabolites of parthenits (Ginetsinskaya, 1968).

Preferable place of the trematode parthenitae invasion, admittedly, is the liver (hepatopancreatic gland) of molluscs. Secretory pancreatic cells are spread there. This organ is an extremely high-branched tubular gland. The main function of the liver is the intracellular digestion of proteins, lipids and carbohydrates (Ginetsinskaya, 1968; Kruglov, 2005).

Long-term observations have shown that parthenitae of Schistosomatidae and Bilharziellidae representatives parasitize exclusively the hepatopancreatic gland of molluscs (Azimov, 1975, 1986; Shakarboev, 2009; Akramova, 2011; Akramova et al., 2007, 2010 a, b, 2011; Horak et al., 2002). However, data on changes in the structural organization of the mollusc liver under the influence of parthenitae and cercariae of above mentioned trematodes are extremely fragmentary and insufficient. In this respect, response testing of the mollusc liver contaminated by *Orientobilharzia turkestanica* (Skrjabin, 1913) parthenitae is of great interest.

Material and methods

In 2009–2011, 585 specimens of *L. auricularia* were collected from the water basins of the north-eastern part of Uzbekistan (Tashkent, Syrdarya, Jizzakh regions). To detect contamination of molluscs by *O. turkestanica* parthenitae and cercariae our method was applied (Shakarbaev et al., 2011). In addition, each specimen was placed in separate water glass (50–100 mL) at 25–30 °C. Under such conditions infected molluscs were generating cercariae for 1–2 hours. Specimens of molluscs infected by *O. turkestanica* and uninfected ones of the control were used for histological examination.

The material for histological study was 22 specimens of molluscs. The shells were first removed; the hepatopancreatic glands were extracted and fixed in neutral 10% formaldehyde and 70 % ethyl alcohol. For morphological assessment sections were stained with haematoxylin-eosin according to the method of Van Gieson and Mallory.

Results

The parthenitae and cercariae of *O. turkestanica* (Skrjabin, 1913), the only one species of trematodes, were found in studied molluscs. The average prevalence of infection in examined populations of *L. auricularia* was 1.88 %. Extent of the invasion in some habitats (“Tashmore”, Tashkent region, 2009) ranged from 0.5 % (15.06.2009) to 3.76 % (20.07.2009). Similar results, with insignificant variations of infestation extent, were also observed in June–July of 2010 and 2011.

We studied molluscs of different age, ranging from juvenile yearlings to old (based on the shell size) specimens. Infection was traced only in mature (large and medium sized) specimens of *L. auricularia* from examined populations.

Microstructure analysis of the hepatopancreatic gland from the control specimens, uninfected molluscs, demonstrated that glandular epithelium of the hepatopancreas was formed by hepatic follicles and unaltered hepatic ducts, i. e. acinus and interacinus connective tissue in general preserved (fig. 1).

Parthenitae and cercariae of *O. turkestanica* localized just in the hepatopancreatic gland of the studied *L. auricularia* molluscs. This observation indicates that hepatopancreas is a general collecting-place of parasitizing for the investigated trematode (fig. 2). The parthenitae, however, may be present in the gonads under intensive infection.

Microscopic survey of infected organs indicated noticeable changes of their condition. The hepatopancreatic glands (liver) lost their flexibility, became friable in the

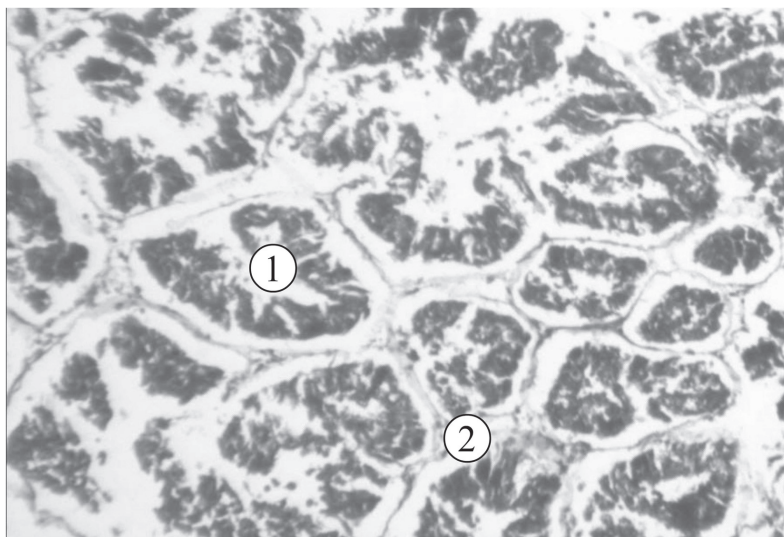


Fig. 1. Microstructure of hepatopancreas *Lymnaea auricularia* (control): 1 — acinus; 2 — interacinus wall. (Objective 10, ocular 10.)

Рис. 1. Микроструктура гепатопанкреаса *Lymnaea auricularia* (контроль): 1 — ацинус; 2 — межацинарная перегородка. (Объектив 10, окуляр 10.)

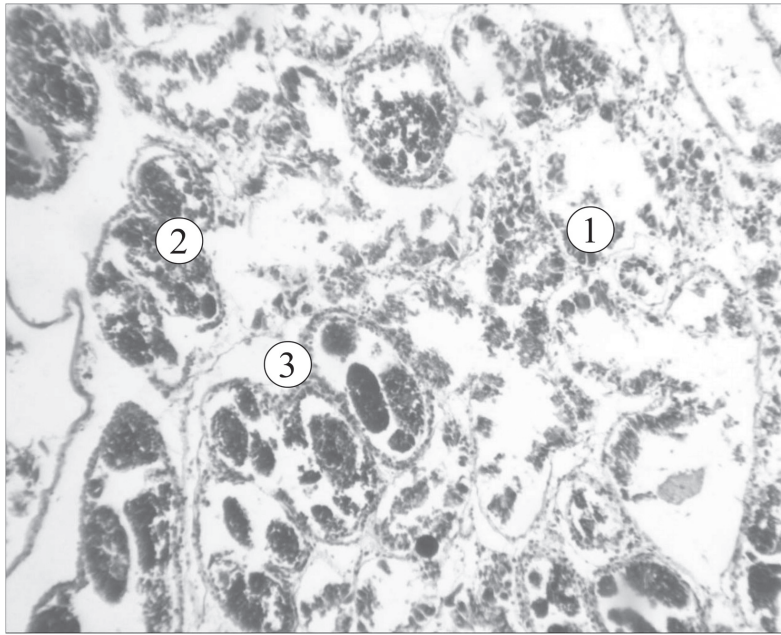


Fig. 2. Microstructure of hepatopancreas *Lymnaea auricularia* infected by *Orientobilharzia turkestanica* larvae: 1 — karyolysis; 2 — karyorrhexis; 3 — pyknosis. (Objective 40, ocular 10.)

Рис. 2. Микроструктура гепатопанкреаса *Lymnaea auricularia* зараженного личинками *Orientobilharzia turkestanica*: 1 — кардиолизис; 2 — кариорексис; 3 — пикноз. (Объектив 40, окуляр 10.)

texture and augmented because of the distending and overfill by parthenitae. On a brown pigmentation of the liver there were clearly visible sporocysts of a milky-white colour penetrating the liver parenchyma. The colour of hepatopancreas becomes grayish-yellow and whitish-green in the specimens infected by parthenitae and cercariae.

Histological study of all examined sections showed that parthenitae and cercariae mainly infected the connective tissue of the hepatopancreatic gland. The pathogenic effect of parasites on the host organism was expressed in the mechanical disturbance of the connective tissue and acini. The connective tissue disintegrated later. There were also areas of cellular detritus. The lacunar interstices and blood tubules were compressed during heavy infection. In addition, oxygen and nutrient supply to the nearest areas of the connective tissue had been stopped.

Therefore, the consequent degradation and necrotic changes were observed in the cellular elements of the connective tissue, fibrillar structures and in the basal substance. Nuclei of the connective-tissue cells, in most cases, were notable for a high level of resistance. During disintegration of the cells they remained in the interacinus interstices unmodified for a long time. Other fibrillar structures of the connective tissue were also exposed to destruction. Reticular fibers did not form networks, and were observed in the interacinus interstices as fragments.

Intensive contamination of the hepatopancreas by trematode larvae provoked its essential augmentation. Such enlargement is not a gland hypertrophy, as its size is not related to the tissue growth, but depends on the accumulation of parasites therein. Following an infection of the hepatopancreas the number of acini was significantly decreased in it.

Acini are pushed aside to the organ's periphery by the parasites concentrated in its central part. And, generally, most of acini were subjected to degradation.

Parasites destroying the interacinus connective tissue and accumulating between the acini pressured them. The walls of the acini, meanwhile, exhibited closer disposition, their lumen decreased and often finally completely disappeared. Constituent cells of

the acini walls were distorted, became shorter and flattened. In that period a rapid autolysis happened in the liver and calciferous cells of the hepatopancreas. That was testified by a significant increase in size and number of the vacuoles filled, apparently, with decomposition products of the cells content that had undergone partial autolysis. In cells of the infected hepatopancreas, changes in the disposition of liver cells nuclei were observed. Meantime, degenerative disorders and necrosis (pycnosis, karyorhexis, karyolysis) proceeded there.

The shape of cells altered, the cell walls distorted and became sinuous, the cell membranes perforated in the apical part and their content poured out into the lumen of acini.

Discussion

It is recognized that significant changes take place in histological structure of the hepatopancreas and other organs of the molluscs under the effect of highly intensive infection by parthenitae and cercariae of different groups of trematodes.

Along with a vast necrotic collapse of hepatopancreatic glands, serious destructive changes in other organs of molluscs with ensuing consequences are observed (Stadnichenko, 1972, 1974; Stadnichenko et al., 1981, 1983). These data are also confirmed by recent investigations on the effect of parthenitae and cercariae from the families Schistosomatidae and Bilharziellidae on the molluscs' organism and its metabolic activity (Morand et al., 1996; Zhang et al., 2001; Sapp, Loker, 2000; Hahn et al., 2001 a, b; Russo, Lagadic, 2000; Horak et al., 2002).

Thus, the parasitism of parthenitae and cercariae of *O. turkestanica* in the body of *L. auricularia* causes profound histopathological changes in the tissues. In this case, significant disorders of metabolism (proteins, carbohydrates and fats) are present and result in weakening of the molluscs' body, and loss of their lability which is essential for adaptation to the environment. The latter is confirmed by a fact of high mortality of infected individuals under fluctuations and divergence of environmental parameters from the optimal ones for this species.

References

- Akramova F. D.* Trematodes of bilharziellides, their origin and evolution : Abstract of thesis ... doct. boil. sci. — Tashkent, 2011. — 46 p. — Russian : *Акрамова Ф. Д.* Трёматоды бильгарциеллиды, их происхождение и эволюция.
- Akramova F. D., Shakarboev E. B., Golovanov V. I et al.* A life cycle of trematode *Dendritobilharzia loossi* (Schistosomatida, Bilharziellidae), a parasite of waterfowl // *Vestnik zoologii*. — 2007. — **41**, N 6. — P. 511–520. — Russian : *Акрамова Ф. Д., Шакарбоев Э. Б., Голованов В. И.* и др. Жизненный цикл трёматоды *Dendritobilharzia loossi* (Schistosomatida, Bilharziellidae) — паразита водоплавающих птиц.
- Akramova F. D., Azimov D. A., Shakarboev E. B.* Morphology and biology of the trematode *Gigantobilharzia acotylea*, a parasite of Anatidae and Laridae birds in Uzbekistan // *Zoolog. zhurnal*. — 2010 a. — **89**, N 7. — P. 786–795. — Russian : *Акрамова Ф. Д., Азимов Д. А., Шакарбоев Э. Б.* Морфология и биология трёматоды *Gigantobilharzia acotylea* — паразита утиных и чайковых птиц Узбекистана.
- Akramova F. D., Azimov D. A., Shakarboev E. B.* The morphology and biology of the trematode *Gigantobilharzia acotylea* (Digenea, Schistosomatidae) // *Vestnik zoologii*. — 2010 b. — **44**, N 5. — P. 403–412.
- Akramova F. D., Azimov D. A., Shakarboev E. B.* Morphology, biology and taxonomy of *Dendritobilharzia loossi* Skrjabin, 1924 (Trematoda: Bilharziellidae), a parasite of *Pelecanus onocrotalus* (Pelecanidae) and *Anas platyrhynchos* (Anatidae) // *Parasite*. — 2011. — **18**. — P. 39–48.
- Azimov D. A.* Schistosomatides of animals and humans (systematics). — Tashkent : Fan Publishers, 1975. — 152 p. — Russian : *Азимов Д. А.* Шистозоматиды животных и человека (систематика).
- Azimov D. A.* Ecological-taxonomic characteristics of the trematodes from order Schistosomatida (Skrjabin et Schulz, 1937) Azimov, 1970 and bioecological basis of orientobilharziasis of agricultural animals : Abstract of thesis ... doct. boil. sci. — Moscow, 1986. — 37 p. — Russian : *Азимов Д. А.* Эколого-таксономическая характеристика трёматод отряда Schistosomatida (Skrjabin et Schulz, 1937) Azimov, 1970 и биологические основы профилактики ориентобильгарциоза сельскохозяйственных животных.

- Ginetsinskaya T. A.* Trematodes, their life cycles, biology and evolution. — Leningrad : Nauka, 1968. — 412 p. — Russian : *Гинецинская Т. А.* Трематоды, их жизненные циклы, биология и эволюция.
- Hahn U. K., Bender R. C., Bayne C. J.* Killing of *Schistosoma mansoni* sporocysts by haemocytes from resistant *Biomphalaria glabrata*: role of reactive oxygen species // *J. Parasitol.* — 2001 a. — **87**. — P. 292–299.
- Hahn U. K., Bender R. C., Bayne C. J.* Involvement of nitric oxide in killing of *Schistosoma mansoni* sporocysts by haemocytes from resistant *Biomphalaria glabrata* // *J. Parasitol.* — 2001 b. — **87**. — P. 778–785.
- Horak P., Kolarova L., Adema C. M.* Biology of the schistosome genus *Trichobilharzia* // *Adv. Parasitol.* — 2001. — **52**. — P. 155–233.
- Kruglov N. D.* Mollusks of the family Lymnaeidae (Lymnaeidae, Gastropoda, Pulmonata) in Europe and north Asia. — Smolensk : SGPU Publishing, 2005. — 507 p. — Russian : *Круглов Н. Д.* Моллюски семейства прудовиков (Lymnaeidae, Gastropoda, Pulmonata) Европы и Северной Азии.
- Morand S., Manning S. D., Woolhouse M. E. J.* Parasite-host coevolution and geographic patterns of parasite infectivity and host susceptibility // *Proceed. Royal Soc. London. Ser. Biol.* — 1996. — **263**. — P. 119–128.
- Russo J., Lagadic L.* Effects of parasitism and pesticide exposure on characteristics and functions of hemocyte populations in the freshwater snail *Lymnaea palustris* (Gastropoda, Pulmonata) // *Cell Biol. Toxicol.* — 2000. — **16**. — P. 15–30.
- Sapp K. K., Loker E. S.* A comparative study of mechanisms underlying digenean-snail specificity: in vitro interactions between hemocytes and digenean larvae // *J. Parasitol.* — 2000. — **86**. — P. 1020–1029.
- Shakarbaev U. A., Akramova F. D., Golovanov V. I.* The fauna of furcocercaria of trematodes of freshwater mollusks in north-eastern Uzbekistan // *Uzbek Biol. J.* — 2011. — N 6. — P. 44–48. — Russian : *Шакарбаев У. А., Акрамова Ф. Д., Голованов В. И.* Фауна фуркоцеркарий трематод пресноводных моллюсков водоемов северо-востока Узбекистана.
- Shakarboev E. B.* Trematodes of vertebrates animals of Uzbekistan (species composition, ways of circulation and ecological-biological peculiarities) : Abstract of thesis ... doct. boil. sci. — Tashkent, 2009. — 37 p. — Russian : *Шакарбоев Э. Б.* Трематоды позвоночных животных Узбекистана (видовой состав, пути циркуляции и эколого-биологические особенности).
- Stadnichenko A. P.* On pathogenic effect of trematode larvae on *Viviparus viviparus* (L., 1758) (Gastropoda, Prosobranchia) // *Parazitologiya.* — 1972. — **6**, N 2. — P. 154–160. — Russian : *Стадниченко А. П.* О патогенном воздействии личинок трематод на *Viviparus viviparus* (L., 1758) (Gastropoda, Prosobranchia).
- Stadnichenko A. P.* Infection level of *Unio pictorum* and *Anodonta piscinalis* (Mollusca, Lamellibranchia) by parthenitae *Vucephalus polymorphus* baer (Trematodes) the effect of parasites on host organism // *Parazitologiya.* — 1974. — **8**, N 5. — P. 420–425. — Russian : *Стадниченко А. П.* Зараженность *Unio pictorum* и *Anodonta piscinalis* (Mollusca, Lamellibranchia) партенитами *Vucephalus polymorphus* baer (Trematodes) воздействие паразитов на организм хозяев.
- Stadnichenko A. P., Ivanenko L. D., Kolosenko N. A. et al.* Pathomorphological changes in cellular elements of the hemolymph of freshwater lung and Prosobranchia mollusks during their infection by trematode parthenitae // *Parazitologiya.* — 1981. — **15**, N 5. — P. 407–414. — Russian : *Стадниченко А. П., Иваненко Л. Д., Колосенко Н. А. и др.* Патоморфологические изменения клеточных элементов гемолимфы пресноводных легочных и переднежаберных моллюсков при инвазии их партенитами трематод.
- Stadnichenko A. P., Bubon A. B., Litvinchuk R. B.* Pathomorphological changes in the hemolymph corpuscle in freshwater mollusks (Bivalvia, Unionidae, Anodontinae) during their infection by trematode parthenitae // *Parazitologiya.* — 1983. — **17**, N 1. — P. 18–23. — Russian : *Стадниченко А. П., Бубон А. Б., Литвинчук Р. В.* Патоморфологические изменения форменных элементов гемолимфы пресноводных моллюсков (Bivalvia, Unionidae, Anodontinae) при инвазии их партенитами трематод.
- Zhang S. M., Leonard P. M., Adema C. M., Loker E. S.* Parasite responsive IgSF members in the snail *Biomphalaria glabrata*: characterization of novel genes with tandemly arranged IgSF domains and a fibrinogen domain // *Immunogenetics.* — 2001. — **53**. — P. 684–694.

Received 11 January 2013

Accepted 1 October 2013