

UDC [591.69:597.8]:591.5(477.64)

## THE BIOLOGICAL CHARACTERISTICS OF REPRESENTATIVES OF THE GENUS *HEPATOZOON* (APICOMPLEXA, ADELEORINA) IN THE MARSH FROG (*PELOPHYLAX RIDIBUNDUS*) SEPARATE POPULATIONS OF ZAPORIZHZHYA REGION

A. P. Korzh, V. Y. Zadorozhnyaya

Zaporizhzhya National University  
vul. Zhukovskogo, 66, Zaporizhzhya, 69600 Ukraine  
E-mail: 312922@rambler.ru; zadorovic@rambler.ru

**The Biological Characteristic of Representatives of the Genus *Hepatozoon* (Apicomplexa, Adeleorina) in the Marsh Frog (*Pelophylax ridibundus*) Separate Populations of Zaporozhzhya Region.** Korzh A. P., Zadorozhnyaya V. Y. — In blood of frogs in two of seven studied biotopes the presence of the genus *Hepatozoon* representatives was revealed. Morphometric parameters allowed defining a specific accessory of the revealed haemoparasite *Hepatozoon* in a blood channel of village Malozaharino frogs which were closest to the species *H. magna* (Grassi et Feletti, 1891) Labbe, 1899.

**Key words:** hepatozoon, marsh frog, invasion extensiveness, invasion intensity, gamont, erythrocyte.

**Биологическая характеристика представителей рода *Hepatozoon* (Apicomplexa, Adeleorina) в разных популяциях озёрной лягушки (*Pelophylax ridibundus*) Запорожского региона.** Корж А. П., Задорожня В. Ю. — В крови у лягушек в двух из семи изученных биотопов обнаружено наличие представителей рода *Hepatozoon*. Морфометрические параметры позволили определить видовую принадлежность выявленного гемопаразита: *Hepatozoon* в кровяном русле лягушек с. Малозахарино наиболее близок к виду *H. magna* (Grassi et Feletti, 1891) Labbe, 1899.

**Ключевые слова:** гепатозоон, озёрная лягушка, экстенсивность инвазии, интенсивность инвазии, гамонт, эритроцит.

### Introduction

The genus *Hepatozoon* (Miller, 1908), of the family *Hepatozoidea* (Wenyon, 1926) is presented by more than 50 species that are exclusively intracellular hemoparasites. They are common in all groups of vertebrates and some invertebrates (Smith, 1996; Satetaset et al., 2009). Initially, the representatives of the genus *Hepatozoon* had combined with the genus *Haemogregarina* (Siddall, 1995), but they were separated into a particular genus (Mathew et al., 2000) after the phylogenetic analysis. One of the distinguishing features of the genus *Hepatozoon* is the presence of cystiform formations in the liver of a vertebrate host animal infected with these parasites. It is known that these cysts are surrounded by inflammatory cells (Faggioni et al., 2006; Levine, Richard, 1977).

Representatives of this genus can parasitize leukocytes in birds and mammals, as well as red blood cells in reptiles, amphibians and fish. All vertebrate animals infected with this hemoparasites are intermediate hosts (Smith, 1996).

Study of distribution of *Hepatozoon* from anurans, especially frogs, and their host-parasite relationship are of great interest.

Frogs are fairly common, and due to the specifics of ontogeny they are the links between aquatic and terrestrial ecosystems. These amphibians are important in food chains, ensuring the normal functioning of biocenosis. It is known that the frog can be both intermediate and definitive host for some parasites and infected individuals can be dangerous for animals that feed on them (Barta, Desser, 1984; Gayibova, Mamedova, 2010).

In Ukraine, *Pelophylax ridibundus* Pall., 1771 is a quite common species that penetrates south steppe zone along the valleys of large rivers (Pisanets, 2006). Perhaps that is why this form is susceptible to a large range of parasites. Mites, predatory beetles, mosquitoes, gnats, flies, lice, fleas and leeches being the vectors of the parasite (Smith, 1996; Faggioni et al., 2006) can be definitive hosts of *Hepatozoon*.

Despite the geographical distribution and the biological significance of the *Hepatozoon* species, their ecological and biological characteristics are not well understood (Readel, Goldberg, 2010). The incompleteness

of the study of anurans blood parasites and the lack of information from certain geographical areas on the availability and distribution of frogs hemoparasites impede formation of a common understanding of the functioning of the present host-parasite systems features.

Understanding the mechanism of interaction in host-parasite relations for the given representatives has significant practical importance. Abundant infestation of final and intermediate hosts by *Hepatozoon* may jeopardize the existence of the respective species.

Therefore, the identification and analysis of the environmental features of given parasitic systems can be crucial for a better understanding of the mechanism of inter-species relationships and the conservation of biological diversity (Stenberg, Bowerman, 2008). The study of amphibian parasites gives background for the assessment of the habitat — the frog may be the indicator of parasitic contamination of water bodies (Gayibova, Mamedova, 2010).

In Ukraine the description of frog hemoparasites was carried out fragmentary (Glushchenko, 1961). In subsequent years, we did not find the data on the identification and study of amphibian infection with these parasites in Ukraine. Therefore, the study of anurans contamination with the genus *Hepatozoon* representatives, including *P. ridibundus*, is relevant.

The aim of the work was the study of the presence and biological characteristics of the genus *Hepatozoon* representatives in populations of *P. ridibundus* in Zaporizhzhya region.

### Material and methods

The studies were conducted during the field season 2010–2012, in inland waters: city of Zaporizhzhya (Park Dubovaja Roshcha and Cosmicheskaya cavin) — N 1 and N 2 samples respectively; town Stepnogorsk — sample N 3; town Volnyansk (pond Bekerovo) — sample N 4, vil. Belenky of Zaporizhzhya region (the river Buckeye) — sample N 5; Orekhovsky area (the river Conca) — sample N 6, vil. Malozaharino of Solonyansky area, Dnipropetrovsk region. (pond Chumatsky) — sample N 7.

Hemoparasites of *P. ridibundus* common for the region anurans were the object of the investigation. In total the blood smears of 121 individuals were studied.

The presence of hemoparasites was discovered in blood smears fixed in 96 % ethanol and stained with azure-eosin Romanovsky-Giemsa (pH = 7.2). Blood smears were examined with the use of immersion lens ( $12 \times 100$ ) of light microscope Micromed 5520. The extent of infestation (EI) — the proportion of infected individuals of on the number of examined, and the intensity of infection (II) — as the amount of erythrocytes infected with parasites, with regard to 1000 examined cells were defined (Gayibova, Mamedova, 2010).

*Hepatozoon* species were identified based on comparative analysis of morphometric parameters of developmental stages (Smith, 1996).

Morphometric measurements were also made from the affected and unaffected erythrocytes. Measurement of morphometric parameters were performed in microns, and then form index (FI) of erythrocytes and parasite as the length to width ratio of the cell was counted. The data were processed statistically using Statistica 10, the accuracy of the differences between groups were analyzed using the Student t-test.

### Results and discussion

In the blood of frogs *P. ridibundus* from the studied area, *Hepatozoidea* intraerythrocyte hemoparasites were identified in two samples (N 2 and N 7). Anatomical dissection of frogs and visual examination of inner organs showed cystiform formations of varying severity in almost all individuals infected with *Hepatozoon*. Cystic formations were located mainly in the liver, spleen and kidneys among the internal organs. In the blood sample N 7 different stages of *Hepatozoon* — extracellular form, as well as intracellular forms (mature and young gamonts) were found. In frog erythrocytes from the sample N 2 only two stages of the parasite — the extracellular form and the mature gamont (intracellular form) were detected.

Extracellular form (fig. 1) is an ectoglobular stage of *Hepatozoon* development, which has an elongated worm-like body with rounded and narrowed slightly curved ends. This stage is unevenly painted in slightly purple color. The nucleus of the parasite has a granular structure, well-differentiated, occupies the full width of the body and divides it into two unequal parts. Stained nucleus gains a darker shade so becomes well differentiated.

After the parasite penetration into the red blood cell the gamont with varying degrees of maturity (fig. 2) was formed. Young gamont had banana-like oblong shape with granular structure of nucleus well painted in pink and purple, located in the central part of the parasite body, but not always well differentiated.

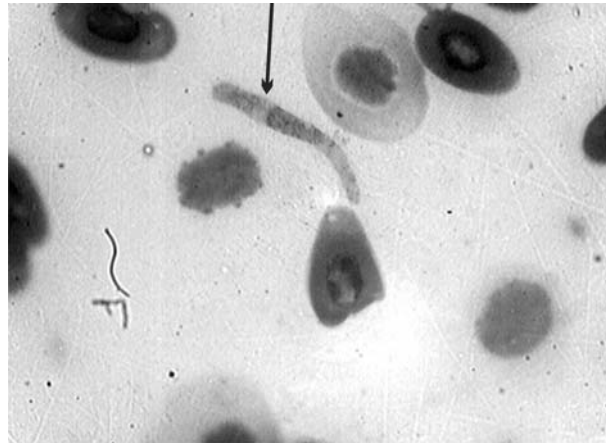


Fig. 1. Extra-erythrocyte form of *Hepatozoon*.

Рис. 1. Внеэритроцитарная форма *Hepatozoon*.

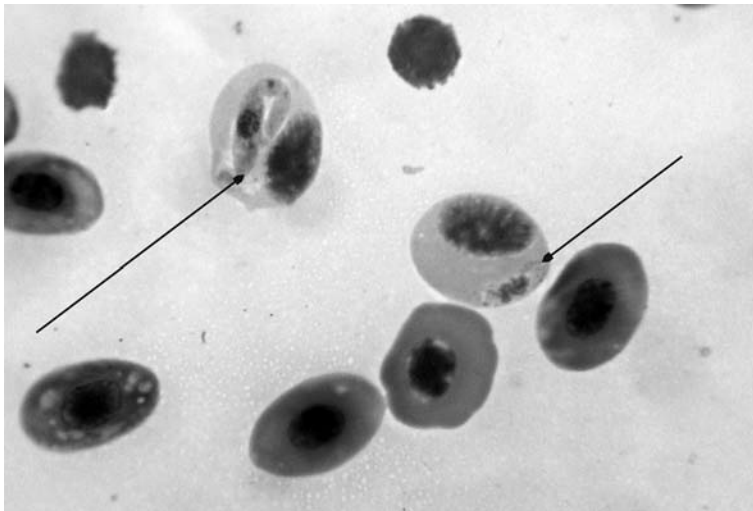


Fig. 2. Young (on the right) and mature (on the left) gamonts of *Hepatozoon*.

Рис. 2. Молодой (справа) и зрелый (слева) гамонт *Hepatozoon*.

In this case the affected erythrocytes were somewhat increased in size compared to the unaffected cell. Erythrocyte cytoplasm acquired a blue-gray hue. The nuclei of the affected cells were not segmented, and shifted laterally or polar.

The mature gamont may be placed inside the erythrocyte cells either along or across it, which in turn affected its form. Inside the cell hemoparasite became O- or S-shaped. Around its body the parasitiform vacuole of varying degree of manifestation was formed. On stained blood smears, the body of the parasite gained blue-violet hue. The nucleus of the mature gamont spans the entire width of the parasite body. It is well-differentiated, has a granular structure and divides the body into two unequal parts.

Red blood cells with *Hepatozoon* inside increased in size, their cytoplasm changed its color, getting a gray-blue tint in contrast to the cytoplasm of the unaffected erythrocyte.

Analysis of the morphometric characteristics (table 1) of unaffected frog erythrocytes and their FI showed no significant differences in the individuals of two samples, where *Hepatozoon* was found. No significant differences were found in frogs of N 2 and N 7 samples when using morphometric analysis of nuclei of parasitized erythrocytes. When

**Table 1.** Comparison of the morphometric indicators of different stages of *Hepatozoon* development and *P. ridibundus* blood cells

**Таблица 1.** Сравнительная характеристика морфометрических показателей разных стадий развития *Hepatozoon* и клеток крови лягушки *P. ridibundus*

INVESTIGATED FACTOR	Vil. Malozaharino (n = 15)						Zhaporizhzhya city Cosmicheskaya cavin (n = 13)					
	length, μm	width, μm	min length/width.	max length/width.	Cv, % length/width.	FI	length, μm	width, μm	min length/width.	max length/width.	Cv, % length/width.	FI
Ectoglobular gamont	32.06 ± 0.45	3.71 ± 0.12	25/2	37/5	8.28/19.12 ± 0.33	8.95	28.88***	2.88*** ± 0.47 ± 0.09	26/2	32/3	6.56/11.88	10.23* ± 0.45
Nucleus of ectoglobular gamont	6.06 ± 0.20	3.71 ± 0.12	4/2	9/5	19.99/19.12	1.70 ± 0.09	5.25***	2.88*** ± 0.14 ± 0.09	4/2	6/3	10.99/11.88	1.84 ± 0.06
Young gamont	12.27 ± 0.24	5.72 ± 0.14	11/5	14/6	6.40/8.16 ± 0.07	2.16	—	—	—	—	—	—
Mature gamont	35.31 ± 0.48	4.16 ± 0.07	26/3	45/6	12.19/14.53 ± 0.17	8.63	32.18**	3.68*** ± 0.82 ± 0.12	26/3	38/5	11.96/15.42	8.96 ± 0.40
Nucleus of Mature gamont	5.21 ± 0.09	4.16 ± 0.07	4/3	7/6	15.47/14.53 ± 0.03	1.27	5.00 ± 0.13	3.68*** ± 0.12	4/3	6/5	12.34/15.42	1.37 ± 0.04
Affected erythrocyte	25.93 ± 0.30	17.65 ± 0.32	20/11	34/24	10.36/16.03 ± 0.03	1.50 ± 0.41	24.05***	13.81*** ± 0.40	21/11	29/17	7.84/13.28	1.77*** ± 0.06
Nucleus of Affected erythrocyte	13.45 ± 0.23	7.41 ± 0.20	8/5	20/11	15.42/24.45 ± 0.06	1.93 ± 0.29	12.86 ± 0.35	7.05	10/4	15/11	10.23/22.65	1.93 ± 0.11
Unaffected erythrocyte	21.42 ± 0.23	12.33 ± 0.19	15/9	31/21	10.76/14.10 ± 0.04	1.77 ± 0.29	21.93 ± 0.19	12.3	20/10	26/15	7.18/8.58	1.80 ± 0.04
Nucleus of unaffected erythrocyte	9.4 ± 0.13	5.76 ± 0.08	7/4	13/8	12.04/13.02 ± 0.03	1.65 ± 0.23	8.97 ± 0.16	5.13	6/4	13/7	13.89/17.52	1.80 ± 0.07

**Note.**\* — p < 0.05; \*\* — p < 0.01; \*\*\* — p < 0.001.

comparing the morphometric parameters of parasitized erythrocytes the significant increase by 7,80 % of length and 27.80 % (P < 0.001) of width was found in the sample N 7, but the FI of red cells was less than 15.25 % (P < 0.001).

Ectoglobular form of frogs blood sample N 7 was significantly higher for 10 % (P < 0.001) in length and for 22.37 % (P < 0.001) in width of the dimensional characteristics of parasites found in the blood of frogs sample N 2. FI of the extracellular forms of urban population was significantly higher for 12.5 % than the FI for parasites of the rural area.

Significant differences of morphometric parameters were observed when comparing mature *Hepatozoon* gamont. Parasite in the sample N 7 in length by 9 % (P < 0.01), and in width by 11.5 % (P < 0.001) exceeded the dimensional parameters for sample N 2. Nuclei of mature gamont did not have significant differences in length in the two samples, and in the width the specimens from the sample N 7 were smaller by 11.5 %. Such differences were not observed for FI. The coefficient of variation of morphometric parameters for all stages of *Hepatozoon* from the frogs blood sample N 7 ranged 6.40–19.99 %.

Margins of the coefficient of variation fluctuation for the urban sample were 6.56–15.42 %. The most variable rate was the length and width of the extracellular form. The nucleus of the parasites at this stage from the frogs blood sample N 2 had a lower coefficient of variation than the sample N 7.

The *Hepatozoon* II was found higher in 1.76 times in the frog of the genus *Pelophylax* from the sample N 7 compared with the sample N 2 (table 2). For the sample N 7 excess by 49.86 % for EI was also observed, even though in both populations this figure is quite high.

Thus, in general it can be argued that frogs from urban populations have a higher rate of infection.

Table 2. Rate of *P. ridibundus* infection with *Hepatozoon* from Zaporizhzhya region reservoirsТаблица 2. Степень заражённости *Hepatozoon* лягушек *P. ridibundus* из водоемов Запорожского региона

N sample	II, %				EI, %
	$\bar{X} \pm S_x$	min	max	Cv, %	
2	5.75 ± 1.84	2.21	9.64	64.11	44.44
7	10.12 ± 3.58	1.30	25.10	86.69	66.60

Despite the fact that *Hepatozoon* caused the same external changes in the red blood cells of *P. ridibundus* of studied biotopes, morphometric characteristics of the hemoparasite found in the blood of frogs of different samples were significantly different. Thus, the findings may indicate that the *Hepatozoon* of frogs of Malozaharino village and Cosmicheskaya cavin of Zaporizhzhya city belongs to different species.

According to the literature, the highest representation of *Hepatozoon* is detected for *P. ridibundus*: *H. magna* (Grassi et Feletti, 1891) Labbe, 1899 (Malysheva, 2009), *H. medinensis* (Shalaby, Banaja et Al-Ghamedi, 1994) (Smith, 1996), and others (Abd-Allah Shazl, 2003). For *P. esculentus* (L., 1758) one species — *H. hortai* (Brumpt, 1929) (Smith, 1996) is recorded, but its morphometric characteristics were not found in publications. We have not found literature that describes the types of *Hepatozoon* parasitic in the blood of *R. lessonae* (Camerano, 1882).

It should be noted that today the life cycle of only two species of *Hepatozoon* parasitic in the blood of marsh frogs — *N. catesbiana* (Stebbins, 1904) and *H. clamatae* (Stebbins, 1905) Lehmann, 1960 emend. Levine, 1985 is well-studied and described. Based on genetic analysis the genetic independence of these species was identified, but the scheme of their life cycles is common (Smith, 1996; Desser et al., 1995; Kim et al., 1998; Smith et al., 1999). Despite sufficient wealth of information on the life cycle of *Hepatozoon*, there are still much unresolved issues. In particular, a circulation mechanism of the parasite in the intermediate host remains to be studied.

The findings suggest that frogs hemocytozoon of a population from Malozaharino village is the closest to the species *H. magna* (Grassi et Feletti, 1891) Labbe, 1899, described in *P. ridibundus* from Kyrgyzstan (Malysheva, 2009). We identified that *Hepatozoon* from Cosmicheskaya cavin by its morphometric characteristics does not match the previously described species. Thus, *Hepatozoon* detected in the blood of *P. ridibundus* sample of Zaporizhzhya city should be considered as *Hepatozoon* sp.

The data of 2012 (Malozaharino village, first decade of May) showed the presence of mature gamonts in erythrocytes of hibernating frogs. Also the absence of cystiform formations on the internal organs was detected, that may indicate a change of invasion titer at this time. According to the other authors (Desser et al., 1995; Kim et al., 1998), infection of the final host (vector) is possible only from the intermediate one (transovarial transmission of the parasite is absent). Thus, this suggests that the frogs are the natural reservoir of *Hepatozoon* parasites.

In further it is planned to continue the study of marsh frogs' infection with *Hepatozoon* homoparasites in Zaporizhzhya region.

## Conclusions

1. The presence of the genus *Hepatozoon* representatives was detected in marsh frogs of Zaporizhzhya region in two of seven studied habitats. In frogs caught from inland of water body in Cosmicheskaya cavin of Zaporizhzhya city, EI and II of *Hepatozoon* was 1.5 and 1.76 times, respectively, higher compared to the amphibians from biotope of Malozaharino village.

2. Observed no differences between the unaffected erythrocytes, while parasitized erythrocytes had significant differences in all morphometric parameters. In frogs from the



pond of Malozaharino village these characteristics increase the rates of individuals from the Cosmicheskaya cavin in length of erythrocyte by 7.80 % ( $p < 0.001$ ) and in width — by 27.80 % ( $p < 0.001$ ), meanwhile FI of infected erythrocytes was less than 15,25 % ( $p < 0.001$ ).

3. According to the morphometric characteristics hemoparasites in the bloodstream to the frog from pond of Malozaharino village are more similar to *H. magna*.

4. *P. ridibundus* is supposedly a natural reservoir for parasites of the genus *Hepatozoon*.

The authors express their sincere thanks to Dr. Hamid Davudovne Gayibov and Ph. D. Mairu Alievich Huseynov of the Institute of Zoology of Azerbaijan National Academy of Sciences for providing advice in conducting research and analyzing the data.

## References

- Gayibova G. D., Mamedova S. O. Hemoparasites of the lake frog *Pelophylax ridibundus* from water bodies in Azerbaijan // The Journal of V. N. Karazin Kharkiv National University. Ser. Biology. — 2010. — Is. 12, N 920. — P. 54–60. — Russian : Гаубова Г. Д., Мамедова С. О. Кровепаразиты озерной лягушки *Pelophylax ridibundus* из водоёмов Азербайджана.
- Glushchenko V. V. Parasitofauna of blood of amphibians and reptiles the middle reaches of the Seversky Donets // Proceed. of the Ukr. Scien. Soc. of Parasit. — 1961. — N 1. — P. 235–249. — Russian : Глущенко В. В. Паразитофауна крови амфибий и рептилий в районе среднего течения Северского Донца.
- Malysheva M. N. To the fauna of hemoparasites anurans (Anura) Kyrgyzstan // Parasitology. — 2009. — **43**, N 1. — P. 32–45. — Russian : Мальшева М. Н. К фауне кровепаразитов бесхвостых амфибий (Anura) Киргизии.
- Pisanets E. M. The Ukrainian Amphibian Fauna: Issues of Diversity and Taxonomy. Communication 2. Anuran Amphibians (Anura) // Zbirnyk Prats zoologichnogo museiu. — 2006. — N 38. — P. 44–79. — Russian : Писанец Е. М. Фауна амфибий Украины: вопросы разнообразия и таксономии. Сообщение 2. Бесхвостые амфибии (Anura).
- Abd-Allah Shazl M. Erythrocytic and merogonic stages of *Hepatozoon ridibundae* sp. nov. infecting the Arabian ranid frogs, *Rana ridibunda* in Saudi Arabia with reflections on the haemogregarine complex // J. Egypt Soc. Parasitol. — 2003 Aug. — 33 (2). — P. 497–516.
- Barta J. R., Desser S. S. Blood parasites of amphibians from Algonquin Park, Ontario // J. Wildl. Dis. — 1984. — **20**, N 3. — P. 180–189.
- Desser S., Hong H., Martin D. The life history, ultrastructure, and experimental transmission of *Hepatozoon catesbiana* N. comb., an Apicomplexan parasite of the bullfrog, *Rana catesbiana* and the mosquito, *Culex territans* in Algonquin park, Ontario // J. Parasitol. — 1995. — **81**, N 2. — P. 212–222.
- Faggioni C., Latimer K., LeRoy B. Haemogregarines in reptiles and amphibians // <http://www.vet.uga.edu/vpp/clerk/faggioni/index.php>. 2006.
- Kim B., Smith T. G., Desser S. S. The life history and host specificity of *Hepatozoon clamatae* (Apicomplexa: Adeleorina), and ITS-1 nucleotide sequence variation of *Hepatozoon* species of frogs and mosquitoes from Ontario // J. Parasitol. — 1998. — **84**, N 4. — P. 789–797.
- Levine N., Nye Richard R. A survey of blood and other tissue parasites of leopard frogs *Rana pipiens* in the united states // J. Wildl. Dis. — 1977. — **13**. — P. 17–23.
- Mathew J. S., Bussche V. D., Edwing S. A. et al. Phylogenetic relationships of *Hepatozoon* (Apicomplexa: Adeleorina) based on molecular, morphologic, and life-cycle characters // J. Parasitol. — 2000. — **86**, N 2. — P. 366–372.
- Readel A. M., Goldberg T. L. Blood Parasites of Frogs From an Equatorial African Montane Forest in Western Uganda // Amer. Soc. of Parasitol. — 2010. — **96**, N 2. — P. 446–450.
- Satetasiit J. M., Chutmongkonkul M., Sailasuta A. Blood Parasites of the Rice Field Frog, *Hoplobatrachus rugulosus* (Wiegmann, 1835), from Wang Nam Yen district, Sra-kaew Province, Thailand // Proceed. 8th Chula. Univ. Vet. Sci. Ann. Con. — 2009. — April 3.
- Shutler D., Smith T. G., Robinson S. R. Relationships between leukocytes and *Hepatozoon* spp. in green frogs, *Rana clamitans* // J. Wildl. Dis. — 2009. — **45**, N 1. — P. 67–72.
- Smith T. G. The genus *Hepatozoon* (Apicomplexa: Adeleorina) // J. Parasitol. — 1996. — **82**, N 4. — P. 565–585.
- Smith T. G., Kim B., Desser S. S. Phylogenetic relationships among *Hepatozoon* species from snakes, frogs and mosquitoes of Ontario, Canada, determined by ITS-1 nucleotide sequences and life-cycle, morphological and developmental characteristics // Int. J. Parasitol. — 1999. — **29**, N 2. — P. 293–304.
- Stenberg P. L., Bowerman W. J. Hemoparasites in Oregon Spotted frogs (*Rana pretiosa*) from Central Oregon, USA // J. Wildl. Dis. — 2008. — **44**, N 2. — P. 464–468.

Received 4 October 2012

Accepted 21 March 2013